
SPECIAL ARTICLE

HIV Infection and the Abnormal Cervical Cytology

Chenchit Chayachinda, M.D.*,
Apiradee Jirattigalachote, M.D.**,
Sivakorn Chuenchoo***,
Arnon Poorichitiporn***,
Manopchai Thamkhantho, M.D.*

* Department of Obstetrics and Gynaecology, Faculty of Medicine Siriraj Hospital, Mahidol University, Bangkok 10700, Thailand

** Department of Obstetrics and Gynaecology, Faculty of Medicine, Naresuan University, Phitsanulok 65000, Thailand

*** Medical students, Faculty of Medicine Siriraj Hospital, Mahidol University, Bangkok 10700, Thailand

ABSTRACT

Human immunodeficiency virus (HIV) infection has been known as a chronic, immunocompromising condition, which accelerates the natural history of many diseases, including cervical cancer. As known, human papillomavirus (HPV) is the principal etiologic organism and its persistent infection can transform normal cervical cells to cancers. HPV and HIV possibly co-facilitate the transmission of each other. In addition, the co-existence of oncogenic and non-oncogenic HPV appears very common. In 2018, the recommendations provided by the Panel on Opportunistic Infections in HIV-Infected Adults and Adolescents for screening cervical cancer in HIV-infected women were launched. In contrast to the previous guideline by the Center for Disease Control and Prevention (2009) which showed that the screening interval was one year once the first three Papanicolaou (Pap) tests were negative, that in the recent recommendations is three years. Moreover, new techniques such as co-testing are taken into account. The article aims to share our experience at the Siriraj Female Sexually Transmitted Diseases Clinic, Siriraj Hospital, which has been taking care of this special group of population for nearly two decades.

Keywords: HIV, HPV, Pap test.

Correspondence to: Manopchai Thamkhantho, MD, FRCOG., Department of Obstetrics and Gynaecology, Faculty of Medicine Siriraj Hospital, Mahidol University, Bangkok 10700, Thailand, Tel: +66-2-419-4775, Fax: +66-2-419-4997, E-mail: manopchai.tha@mahidol.ac.th

Received: 19 April 2019, **Revised:** 4 May 2019, **Accepted:** 5 May 2019

Introduction

Human immunodeficiency virus (HIV) infection has been known as a chronic, immunocompromising condition, which accelerates the natural history of

many diseases, including cervical cancer. It has been widely accepted that human papillomavirus (HPV) is the principal etiologic cause and its persistent infection can transform normal cervical cells to cancers.

Compared with non-infected women, those living with HIV are more likely to have precancerous and cancerous lesions of cervix⁽¹⁾. Moreover, cervical cancer is one of the most common malignancies associated with acquired immune deficiency syndrome (AIDs) in Thailand⁽²⁾.

At the moment, cervical cancer screening tools have a high yield in early detection of cervical cancer. Evaluation of the morphologically altered cervical cells, or Papanicolaou (Pap) test, and/ or identification of oncogenic/ high risk HPV (hrHPV) appear to be promising tools. Negative results of both tests provide a greater reassurance and allow for a longer follow-up interval⁽³⁾. The reporting system of the Pap rest is based on the Bethesda system⁽⁴⁾, including squamous component (atypical squamous cell of undetermined significance, ASCUS; low grade squamous intraepithelial lesion, LSIL; high grade squamous intraepithelial lesion, HSIL; atypical squamous cell cannot exclude HSIL, ASC-H; and squamous cell carcinoma, SCC) and glandular component (atypical glandular cell, AGC; adenocarcinoma in situ, AIS; and adenocarcinoma).

This review aims to demonstrate trends of abnormal Pap tests in HIV-infected women at the Siriraj Female Sexually Transmitted Diseases (STD) Clinic which has been working in this field for nearly two decades. Moreover, recommendations for screening cervical cancer in this special group of population and its association with genital warts, a disease caused by non-oncogenic HPV, are also included.

HIV infection and the abnormal cervical cytology

HPV and HIV possibly facilitate the transmission of each other⁽⁵⁾. The enhanced HIV-infection susceptibility may be due to the decrease in production of antimicrobial molecules by HPV-infected keratinocytes⁽⁶⁾ which results in easier entry of HIV through the epithelium^(7, 8). In addition, HIV-targeted T cells, including CD4 and CD8 cells, are the predominate cells surrounding high grade cervical intraepithelial neoplasia (CIN3)⁽⁹⁾, which likely

increase HIV entry and replication. Compared with non-infected women, HIV-infected women had higher HPV acquisition (RR 2.64, 95%CI 2.04-3.42) and lower HPV clearance (HR 0.72, 95% CI 0.62-0.84)⁽¹⁰⁾. During the state of immune depletion, HPV persists in the basal cells after lesion regression and can be reactivated⁽¹¹⁾. This may lead to the progression from low-grade to high-grade cervical lesions and finally invasive cancer. Moreover, the HIV-1 Tat protein and gp120 disrupt epithelial tight junctions⁽¹²⁾, causing the expression increment of HPV E6 oncoprotein which downregulates tumor suppressor genes like p53⁽¹³⁾.

Women living with HIV have a greater prevalence of abnormal Pap test⁽¹⁴⁾ and cervical cancer⁽¹⁵⁾. For example, the results of Women's Interagency HIV Study (WIHS), which the Pap tests were obtained every six months for up to eight years, in 1,931 HIV-infected women and 533 non-infected women, showed that the incidence of ASCUS or worse (ASCUS+) was doubled (179 vs 75 in 1,000 person-years) and the incidence of HSIL and SCC was tripled (4.4 versus 1.3 in 1,000 person-years)⁽¹⁴⁾. Additionally, based on an ecological study, compared to general population, HIV-infected women were about nine times more likely to suffer from cervical cancer⁽¹⁵⁾.

Compatible with previous studies^(16, 17), higher prevalence of abnormal cervical cytology was demonstrated in Thai HIV-infected women⁽¹⁸⁾. The prevalence of LSIL or worse (LSIL+) among HIV-infected women was 12.1% (77/636)⁽¹⁹⁾, whereas the rate was 1.1% (261/23,676) in female patients attending the Siriraj Gynaecologic Clinic⁽²⁰⁾. The following report in 2011 showed that, after seven 6-month Pap test, the cumulative incidence of ASCUS+, at which colposcopic examination is recommended⁽²¹⁾, was much higher, at 37%, and CD4 <350 cells/mm³ was the predictive factor⁽²²⁾. During 2007-2017, there were 1,433 new cases of HIV-infected women who attended the Siriraj Female STD Clinic. The worst results of three first Pap tests are shown in Table 1. The decline of new cases is demonstrated while their mean ages appear similar. Apparently, the prevalence of abnormal Pap tests remains being in the spotlight.

Table 1. The worst results of three first pap tests among new cases of HIV-infected women who attended the Siriraj Female STD Clinic during 2007-2017.

Year	2007	2008	2009	2010	2011	2012	2013	2014	2015	2016	2017
Number	143	189	183	166	142	147	142	94	88	70	69
Age (years)	30.2±6.8	32.0±8.8	33.6±9.4	34.1±9.0	34.7±8.9	35.0±9.6	35.1±10.7	36.4±10.5	36.2±11.3	37.3±14.2	37.9±12.0
ASCUS	12 (8.4)	18 (9.6)	17 (9.3)	10 (0.6)	16 (11.3)	13 (8.8)	13 (9.1)	6 (6.4)	8 (9.1)	2 (2.9)	3 (4.3)
LSIL	17 (11.9)	40 (21.3)	28 (15.3)	15 (9.0)	18 (12.7)	15 (10.2)	14 (9.9)	1 (1.1)	4 (4.5)	0	1 (1.4)
HSIL	7 (4.9)	10 (5.3)	7 (3.8)	12 (7.2)	12 (8.4)	8 (5.4)	5 (3.5)	15 (16.0)	14 (15.9)	9 (12.9)	7 (10.1)
ASC-H	1 (0.7)	1 (0.5)	1 (0.6)	3 (1.8)	4 (2.8)	4 (2.7)	1 (0.7)	0	0	0	0
AGC	0	1 (0.5)	0	2 (1.2)	0	1 (0.7)	1 (0.7)	0	2 (2.3)	0	0
Cancer	0	1 (0.5)	5 (2.7)	0	0	0	0	2 (2.0)	2 (2.3)	1 (1.3)	0

ASCUS= atypical squamous cell of undetermined significance, LSIL=low grade squamous intraepithelial lesion, HSIL=high grade squamous intraepithelial lesion, ASC-H=atypical squamous cell cannot exclude HSIL, AGC= glandular component

Co-incident anogenital warts in HIV infection and the abnormal cervical cytology

Anogenital warts (AGWs) are caused by non-oncogenic HPV, mostly type 6 and 11. Our previous report demonstrated that AGWs dramatically increased the incidence of LSIL+, at 16 times higher than that in general gynaecologic patient population⁽²³⁾. This could be explained by 2 theories, including the co-infection and the similar risk factors of non-oncogenic and

oncogenic HPV. The impact scale of HIV on cervical cytology of women with AGWs remains obscured. In our clinic, 53 HIV-infected women presenting with genital warts during 2004-2011 were assessed every six months using a Pap test. Their mean age was 29.4±8.1 years. The median follow-up frequency was three (min-max = 1-21 times and interquartile range = 1-13 times). None of the patients had cervical cancer. The results of the Pap test are shown in Fig. 1.

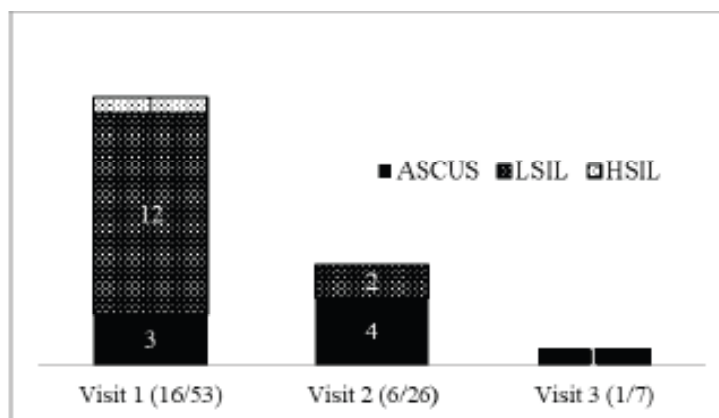


Fig. 1. Incidence of ASCUS+ in the first three visits of 6-month interval in HIV-infected women with anogenital warts. ASCUS = atypical squamous cells of undetermined significance, LSIL = low grade squamous intra-epithelial lesions, HSIL = high grade squamous intra-epithelial lesions

The prevalence of LSIL+ was 24.5% (13/53) at the first visit. This figure is much higher than that among

non-infected cases with AGWs (24.5% vs 16.3%)⁽²³⁾. Colposcopic examination was done for all HIV-infected

women with ASCUS+ and nine cases received biopsy and/or loop electrosurgical excision procedure (LEEP). Of these, high grade cervical intraepithelial neoplasia (CIN III) was reported in five patients. Patient No.1 had HSIL in the first Pap test. Patient No.2 had LSIL in the first Pap test and HSIL in the fifth visit. Patient No.3 had LSIL in the first three visits. Patient No.4 had a negative first Pap test, followed by persistent LSIL. In her 13th visit, patient No.4 had ASC-H before LEEP was done. Patient No.5 had negative Pap test for 10 times and ASCUS at the 11th visit. Based on our experience, many unnecessary colposcopic examinations were performed if considering ASCUS+ as the triage point for the procedure. Therefore, our current guideline is to perform annual Pap test for all patients with AGWs regardless of HIV serostatus and colposcopic examination is recommended only when Pap test is 'LSIL+'.

The screening of cervical cytology in HIV-infected women

For HIV-uninfected women, cervical cancer screening should begin at the age of 21 years regardless of the age of sex debut. Women aged 21-29 years should be screened with cervical cytology alone every 3 years. For women aged 30-65 years, co-testing every 5 years is preferred; however, screening with cytology alone every 3 years is acceptable. Screening should be discontinued up to the age of 65 years^(3, 24). On the contrary, the infected ones should continue the screening program throughout their lives.

A previous study demonstrated the sensitivity and the specificity for detecting CIN II+; at 75.8% and 83.4% for Pap test, and 92% and 51.4% for HPV DNA

testing⁽¹⁰⁾. In HIV-infected women with normal Pap test but positive for oncogenic HPV, a 5-year cumulative risk of CIN II+ was as high as 16%. The subgroup analysis showed that HPV 16 played an important role as the cumulative risk of CIN III was 10% whereas that of HIV-infected women with other hrHPV types was 4%. Therefore, no matter what the Pap test is, those with positive HPV 16 should immediately undergo colposcopic examination⁽¹¹⁾. Recently, co-testing (Pap test plus hrHPV DNA testing) has shown impressive detection rate of high grade CIN.

The WIHS study showed that HIV-infected women with three negative consecutive Pap tests were less likely to have precancerous or cancerous cervical lesions⁽¹⁶⁾. Thus, the Panel on Opportunistic Infections in HIV-Infected Adults and Adolescents launched the recommendations that support early frequent screenings followed by extended intervals⁽²⁵⁾. The initial interval can be 6-monthly or 12-monthly. After three negative results, regular 3-yearly interval is recommended. The age of the patients is one of the most important factors in determining screening practice due to the capacity of self-eradicating an HPV infection.

For those younger than 30 years, a Pap test is the sole screening tool. The recommendations are as in Table 2. HIV-infected women with 'ASCUS' are asked to repeat their Pap tests in the following 6-12 months. Colposcopy is recommended when 'ASCUS+' is reported on the repeat Pap test. In contrast, colposcopy is recommended immediately in case of a 'LSIL+' result. However, if hrHPV DNA testing is done for any reasons and shows positive result concomitantly with ASCUS in the first Pap test, colposcopic examination can be directed to.

Table 2. Recommendations of cervical cancer screening in HIV-infected women aged < 30 years⁽²⁵⁾.

Recommendations	
Age < 21 years, including congenital HIV infection	First Pap test at < 1 year following sex debut or no later than the age of 21 years
Age 21-29 years	First Pap test at the time of HIV diagnosis and every year for the following 2 years. If all Pap tests are negative, the 3-year interval Pap test is recommended thereafter.

For the 'age ≥ 30 years' group, either Pap test or co-testing (Pap test plus hrHPV DNA testing) can be applied. Like the 'age < 30 years' group, Pap test should be done immediately after the diagnosis and should be repeated at the 6-12 month interval. After three first consecutive negative Pap tests, either Pap test or co-

testing at the 3-year interval is recommended. Results and management of cervical cancer screening for HIV-infected women aged ≥ 30 years is shown in Table 3. This is contrasting to the recommendations for the non-infected women in that if the co-testing is negative⁽³⁾, the screening interval will be 5 years.

Table 3. Results and management of cervical cancer screening in HIV-infected women aged ≥ 30 years⁽²⁵⁾.

Pap test	hrHPV test	Management
Negative	Positive for non- HPV 16/18	Repeat co-testing at the following one year. Of the repeated test, if positive for either HPV 16 or HPV 16/18 or 'ASCUS+', colposcopy is recommended.
Negative	Positive for HPV 16 or HPV16/18	Colposcopy
ASCUS	Negative	Repeat Pap test at the following 6-12 months or co-testing at the following 12 months. Of the repeated test, if positive for either HPV 16 or HPV 16/18 or 'ASCUS+', colposcopy is recommended.
ASCUS	Positive for any HPV	Colposcopy
LSIL ⁺	Any	Colposcopy

ASCUS = atypical squamous cells of undetermined significance, LSIL = low grade squamous intra-epithelial lesions, hrHPV = high risk human papillomavirus

The prevalence of cervical cancer and its morbidities are greater in low-middle income countries. Globocan 2012 showed that the incidence of cervical cancer is highest in Asia and the Pacific region⁽²⁶⁾. The age-standardised rate in Thailand vs the United States was 11.3 vs 5.2 per 100,000⁽²⁷⁾. Thus, 6-month intervals of Pap test has been applied for all HIV-infected women in our clinic since 2004. In 2011, we reported that, in 821 HIV-infected women who received 6-month Pap tests during 2004-2009 (2,852 Pap results in total), 'ASCUS+' could be detected in 10% despite the first three negative Pap tests, especially among those with CD4 count ≤ 350 cells/mm³. Of 95 HIV-infected women with ASCUS+, 76 underwent colposcopic examination. LEEP was done in 19 cases and showed 12 high grade CIN and one squamous cell carcinoma⁽²²⁾.

Prevention of HPV infection in HIV-infected women

Similar HPV prevention strategies can be applied

for both HIV-infected women and general population. The basic one is proper condom use. Although HPV can exist in other regions aside from the penis such as scrotal area as well as other parts of external genitalia, a systemic review of longitudinal studies showed that consistent condom use offers effective protection from HPV infection and related cervical neoplasia. Thus, using condoms is a good complementary HPV-preventive instrument⁽²⁸⁾.

Although the HPV vaccination is another propitious strategy, routine screening of cervical cytology remains the priority. Despite the lower immunogenicity among HIV-infected population, vaccination is included in the recommendations⁽²⁵⁾. Currently, a 9-valent vaccine is recommended in some countries such as the United States⁽²⁵⁾ but is still not available in Thailand. The 2-valent or 4-valent HPV vaccines also showed good immunogenic response. However, in a recent phase 3, double-blinded

randomized controlled trial, being conducted in 575 HIV-infected women (aged ≥ 27 years) participants, that evaluated the efficacy of the 4-valent vaccine in protecting against persistent anal infection with HPV 6/11/16/18, anal HSIL after 52 weeks, or persistent oral HPV infection. The study did not support any of the mentioned benefits⁽²⁹⁾.

Conclusion

Abnormal cervical cytology in HIV-infected women has remained highly prevalent during the past decade. As most of them are precancerous lesions, there is a window of opportunity to prevent its progression to cervical cancer. Both the US recommendations and those of the Siriraj Female STD Clinic aim to follow all patients for the rest of their lives. However, the practice in our Clinic suggests the higher screening frequency for Thai HIV-infected women.

Potential conflicts of interest

The authors declare no conflict of interest.

References

1. Ellerbrock TV, Chiasson MA, Bush TJ, Sun XW, Sawo D, Brudney K, et al. Incidence of cervical squamous intraepithelial lesions in HIV-infected women. *JAMA* 2000;283:1031-7.
2. Kiertiburanakul S, Likhitpongwit S, Ratanasiri S, Sungkanuparph S. Malignancies in HIV-infected Thai patients. *HIV Med* 2007;8:322-3.
3. Curry SJ, Krist AH, Owens DK, Barry MJ, Caughey AB, et al. Screening for Cervical Cancer: US Preventive Services Task Force Recommendation Statement. *JAMA* 2018;320:674-86.
4. Nayar R, Wilbur DC. The Pap Test and Bethesda 2014. "The reports of my demise have been greatly exaggerated." (after a quotation from Mark Twain). *Acta Cytol* 2015;59:121-32.
5. Lissouba P, Van de Perre P, Auvert B. Association of genital human papillomavirus infection with HIV acquisition: a systematic review and meta-analysis. *Sex Transm Infect* 2013;89:350-6.
6. Hubert P, Herman L, Maillard C, Caberg JH, Nikkels A, Pierard G, et al. Defensins induce the recruitment of dendritic cells in cervical human papillomavirus-associated (pre)neoplastic lesions formed in vitro and transplanted in vivo. *FASEB J* 2007;21:2765-75.
7. Laurson J, Khan S, Chung R, Cross K, Raj K. Epigenetic repression of E-cadherin by human papillomavirus 16 E7 protein. *Carcinogenesis* 2010;31:918-26.
8. D'Costa ZJ, Jolly C, Androphy EJ, Mercer A, Matthews CM, Hibma MH. Transcriptional repression of E-cadherin by human papillomavirus type 16 E6. *PLoS One* 2012;7:e48954.
9. Monnier-Benoit S, Mauny F, Riethmuller D, Guerrini JS, Capilna M, Felix S, et al. Immunohistochemical analysis of CD4+ and CD8+ T-cell subsets in high risk human papillomavirus-associated pre-malignant and malignant lesions of the uterine cervix. *Gynecol Oncol* 2006;102:22-31.
10. Liu G, Sharma M, Tan N, Barnabas RV. HIV-positive women have higher risk of human papilloma virus infection, precancerous lesions, and cervical cancer. *AIDS* 2018;32:795-808.
11. Doorbar J. Latent papillomavirus infections and their regulation. *Curr Opin Virol* 2013;3:416-21.
12. Tugizov SM, Herrera R, Chin-Hong P, Veluppillai P, Greenspan D, Michael Berry J, et al. HIV-associated disruption of mucosal epithelium facilitates paracellular penetration by human papillomavirus. *Virology* 2013;446:378-88.
13. Barillari G, Palladino C, Bacigalupo I, Leone P, Falchi M, Ensolì B. Entrance of the Tat protein of HIV-1 into human uterine cervical carcinoma cells causes upregulation of HPV-E6 expression and a decrease in p53 protein levels. *Oncol Lett* 2016;12:2389-94.
14. Massad LS, Seaberg EC, Wright RL, Darragh T, Lee YC, Colie C, et al. Squamous cervical lesions in women with human immunodeficiency virus: long-term follow-up. *Obstet Gynecol* 2008;111:1388-93.
15. Chaturvedi AK, Madeleine MM, Biggar RJ, Engels EA. Risk of human papillomavirus-associated cancers among persons with AIDS. *J Natl Cancer Inst* 2009;101:1120-30.
16. Massad LS, Riestler KA, Anastos KM, Fruchter RG, Palefsky JM, Burk RD, et al. Prevalence and predictors of squamous cell abnormalities in Papanicolaou smears from women infected with HIV-1. Women's Interagency HIV Study Group. *J Acquir Immune Defic Syndr* 1999;21:33-41.
17. Minkoff HL, Eisenberger-Matityahu D, Feldman J, Burk R, Clarke L. Prevalence and incidence of gynecologic disorders among women infected with human immunodeficiency virus. *Am J Obstet Gynecol* 1999;180:824-36.
18. Sirivongrangson P, Bollen LJ, Chaovavanich A, Suksripanich O, Virapat P, Tunthanathip P, et al. Screening HIV-infected women for cervical cancer in Thailand: findings from a demonstration project. *Sex Transm Dis* 2007;34:104-7.

19. Chalermchockcharoenkit A, Sirimai K, Chaisilwattana P. High prevalence of cervical squamous cell abnormalities among HIV-infected women with immunological AIDS-defining illnesses. *J Obstet Gynaecol Res* 2006;32:324-9.
20. Laiwejpithaya S, Benjapibal M, Laiwejpithaya S, Wongtiraporn W, Sangkarat S, Rattanachaiyanont M. Performance and cost analysis of Siriraj liquid-based cytology: a direct-to-vial study. *Eur J Obstet Gynecol Reprod Biol* 2009;147:201-5.
21. Kaplan JE, Benson C, Holmes KK, Brooks JT, Pau A, Masur H, et al. Guidelines for prevention and treatment of opportunistic infections in HIV-infected adults and adolescents: recommendations from CDC, the National Institutes of Health, and the HIV Medicine Association of the Infectious Diseases Society of America. *MMWR Recomm Rep* 2009;58(RR-4):1-207.
22. Chalermchockcharoenkit A, Chayachinda C, Thamkhantho M, Komoltri C. Prevalence and cumulative incidence of abnormal cervical cytology among HIV-infected Thai women: a 5.5-year retrospective cohort study. *BMC Infect Dis* 2011;11:8.
23. Chayachinda C, Boriboonhirunsarn D, Thamkhantho M, Nuengton C, Chalermchockcharoenkit A. Number of external anogenital warts is associated with the occurrence of abnormal cervical cytology. *Asian Pac J Cancer Prev* 2014;15:1177-80.
24. Committee on Practice Bulletins—Gynecology. Practice Bulletin No. 168: Cervical Cancer Screening and Prevention. *Obstetrics and Gynecology* 2016;128:e111-30.
25. Panel on Opportunistic Infections in HIV-Infected Adults and Adolescents. Guidelines for the prevention and treatment of opportunistic infections in HIV-infected adults and adolescents: recommendations from the Centers for Disease Control and Prevention, the National Institutes of Health, and the HIV Medicine Association of the Infectious Diseases Society of America. 2018 15 February 2019. Available from: http://aidsinfo.nih.gov/contentfiles/lvguidelines/adult_oi.pdf.
26. Ghebre R, Grover S, Xu M, Chuang L, Simonds H. Cervical cancer control in HIV-infected women: Past, present and future. *Gynecol Oncol Rep* 2017;21:101-8.
27. Torre LA, Bray F, Siegel RL, Ferlay J, Lortet-Tieulent J, Jemal A. Global cancer statistics, 2012. *CA Cancer J Clin* 2015;65:87-108.
28. Lam JU, Rebolj M, Dugue PA, Bonde J, von Euler-Chelpin M, Lynge E. Condom use in prevention of Human Papillomavirus infections and cervical neoplasia: systematic review of longitudinal studies. *J Med Screen* 2014;21:38-50.
29. Wilkin TJ, Chen H, Cespedes MS, Leon-Cruz JT, Godfrey C, Chiao EY, et al. A Randomized, Placebo-Controlled Trial of the Quadrivalent Human Papillomavirus Vaccine in Human Immunodeficiency Virus-Infected Adults Aged 27 Years or Older: AIDS Clinical Trials Group Protocol A5298. *Clin Infect Dis* 2018;67:1339-46.